

IMAGES

in
PAEDIATRIC
CARDIOLOGY

Original article Erdöl C¹, Öztürk C², Öcal A², Bozat T¹, Koca V¹, Özdemir A².
Contralateral recurrence of atrial myxoma - case report and review of the literature. Images Paediatr Cardiol 2001;8:3-9

Division of Cardiology¹ and Cardiovascular Surgery², Yüksek İhtisas Hospital, Duaçınari -BURSA, TÜRKİYE

MeSH

Cardiac Myxoma

Contralateral Recurrence

Abstract

Cardiac myxomas are the most frequent cardiac tumors, and they have the capability for recurrence years after resection, in the same or in different cardiac chambers. Hence, follow-up is important. Contralateral recurrences of myxoma are uncommon. We report a 7 year old boy who had a right atrial myxoma resected, and who had recurrent myxoma in the left atrium. The literature regarding such recurrence is reviewed.

Article

Introduction

Myxomas are the most common primary cardiac tumors, comprising 30-50% of the total in most pathological series. More than 90% per cent of myxomas have been reported to occur sporadically.^{1,2} The recurrence rate of excised myxomas is between 5% and 14%, with most recurrences at the original tumor site. Only a few cases have been reported of remote recurrence in excised myxomas. The mean age of patients with sporadic myxoma is above 50 years, and 70 per cent are females. Myxomas are rare in teenagers and are extremely uncommon in preschool children. Approximately 86 per cent of myxomas occur in the left atrium, the usual site of attachment is in the area of the fossa ovalis. Myxomas may recur in the same or different cardiac chambers.^{3,4} We report a 7 year old boy who had a right atrial myxoma resected, and who had recurrent myxoma in the left atrium.

Patient

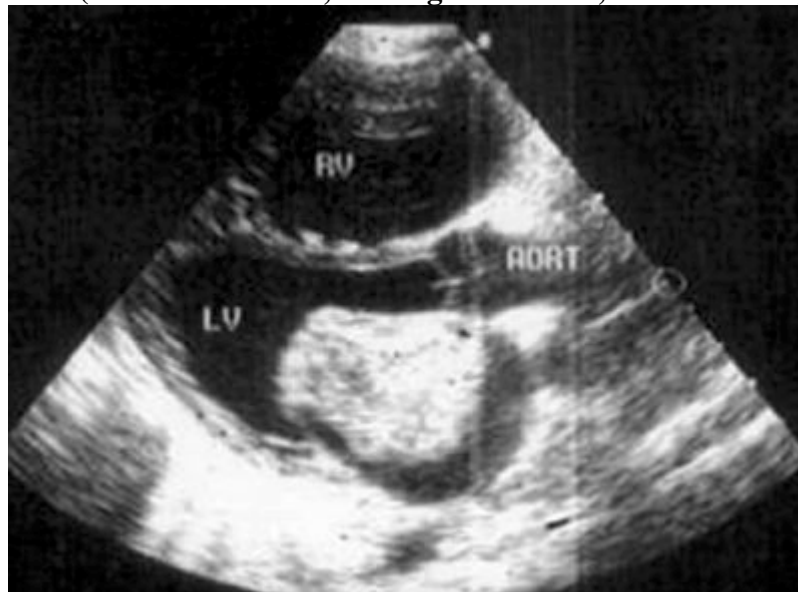
A 7-year-old boy complaining of dyspnea and fatigue was admitted to the Cardiology Division of our hospital with a previous history of right atrial myxoma. He had been operated on 2 years prior for right atrial myxoma. The myxoma had been resected from the interatrial septum with its pedicle, and the defect had been repaired with a Dacron patch. He had no familial history of cardiac tumors.

On physical examination at arrival, blood pressure was 90/50 mmHg, pulse rate 115/min, and he was tachypnoeic. His liver was palpable at 6 cm below the costal margin, and his jugular venous pressure was slightly elevated. Auscultation revealed a mild systolic murmur suggestive of both mitral and tricuspid insufficiency, and a prominent pulmonary component to the second heart sound was also noted. There was evidence of ascites in the abdomen. The skin was normal.

Electrocardiography showed sinus tachycardia, and right ventricular hypertrophy. Chest X-ray showed minimal cardiac enlargement. Other laboratory tests were within normal limits.

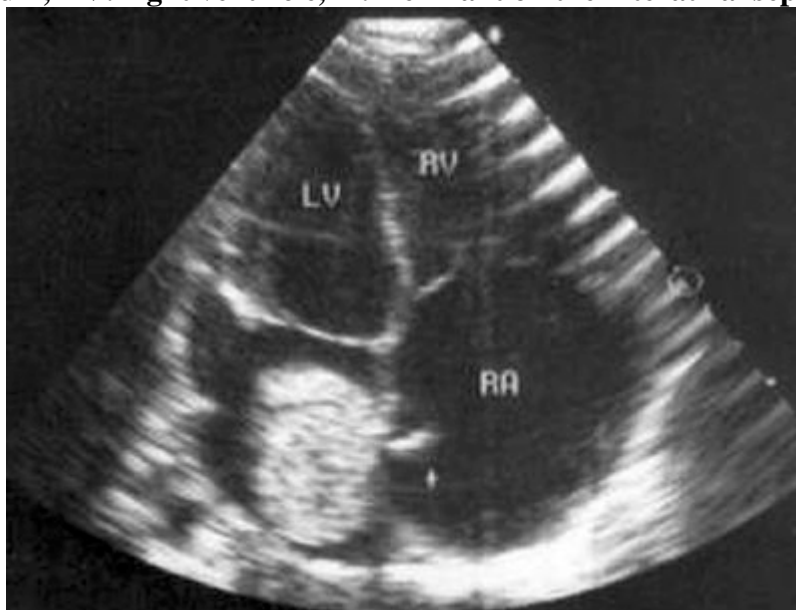
Echocardiographic examination revealed a large left atrial myxoma (approximately 40 by 34 mm). The myxoma arose from the interatrial septum of the left atrium. It was mobile during systole and diastole, almost completely obstructing the mitral orifice (figure 1).

Figure 1: Figure 1: Echocardiographic image of myxoma in parasternal long axis view (LV: left ventricle, RV: right ventricle, AORT: aorta)



There was little remnant on the septal surface of the right atrium (figure 2), and mild enlargement of all cardiac chambers was present. Colour Doppler examination showed mild mitral and tricuspid insufficiency.

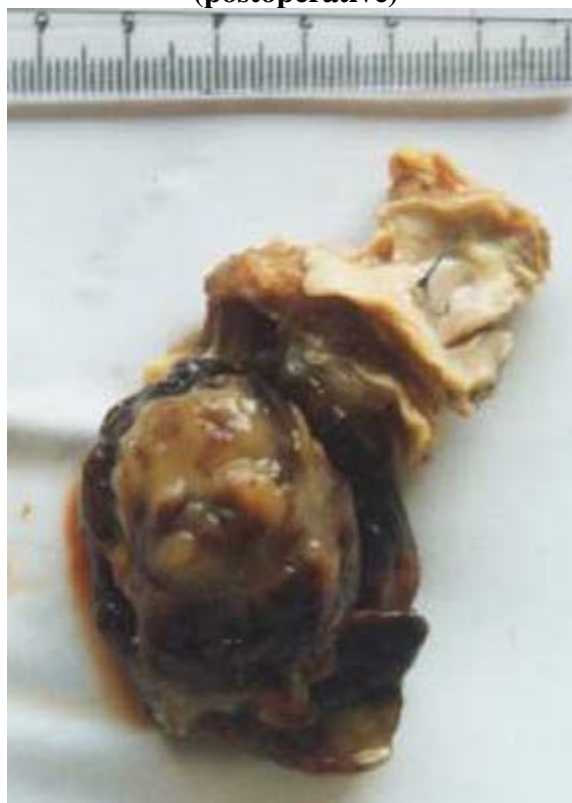Figure 2: Echocardiographic image of myxoma on the interatrial septum (Note the mark on the left side of interatrial septum) (LV: left ventricle, RA: right atrium, RV: right ventricle, + : Remnant on the interatrial septum)



A large myxoma along with its pedicle were totally excised at open-heart surgery (figure 3) through a right atrial approach. The atrial septum was reexcised and reconstructed with a Dacron patch. The dimensions of the excised septum were 40 by 40 mm. There were no further tumors within rest of the cardiac chambers. The operation and subsequent recovery were uncomplicated.

Histologically, the tumor had the typical appearance of a benign myxoma composed of gelatinous appearing material with few cells and no mitotic activity.

Figure 3: Macroscopic image of myxoma (postoperative)



Discussion

Myxomas are very common in the left atrium. They may also occur in the right atrium, and less commonly, in the right or left ventricle. Multiple tumors may occur in the same chamber or in a combination of chambers.² Myxomas may be familial,⁴ and if so, they appear to be transmitted in an autosomal dominant manner.^{1,2}

Patients with recurrent myxoma tend to be younger than patients with sporadic myxoma.¹ Recurrence may be due to implantation of tumor cells during the first operative procedure, or regrowth from the original site due to incomplete excision. Recurrence of cardiac myxomas may be in the same chamber, and/or different chambers.

Although most reviews on cardiac myxomas do not report recurrence,⁵⁻⁹ several reviews have commented with regard to recurrence.^{1,10-21} Recurrences of myxomas are rare and contralateral recurrences are extremely rare in the literature.

Recurrent myxomas may be familial^{4,22,23} or non-familial.^{15,24} Takashi,¹⁰ Martin,¹¹ Dang,¹⁵ Aroca,²⁴ Fagan,²⁵ Fujiwara,¹⁸ and Ohshima²² have reported contralateral recurrences of cardiac myxomas. Table 1 and Table 2 summarise these reports. Martin¹¹ and Ohshima²² both reported primary right atrial myxomas that recurred in the left atrium. However, both patients were adults.

Table 1: Sporadic recurrences of myxomas in the literature

Author	Ref.	Year	Age	Sex	Primary	Recurrence	Time interval
Jugdutt	27	1975	A		LA	LA	31 months
Dang	15	1976	A	M	LA	RV	18 months
Takashi	10	1982	27	F	LA	RA+RV+LA	4 years
Fujiwara	18	1986	A	F	LA	RA	
Martin	11	1987	20	F	RA+LV	LA	4.5 years
Pavlidis	19	1989	A	M	LA	LV	
Fagan	25	1990	A	F	RA	RV	2 years
Ohshima	22	1990	27	F	LA	LA+RA+RV	4 years
Ohshima	22	1990	13	F	RA	LA	3 years
Miyata	26	1990	47	F	RA+LA	RA+LA	6 months
Zeybek	16	1991	22	M	LA	LA	14 years
Haught	23	1991	34	F	LA	LA	
Soma	20	1992	23	F	LV	LV	10months
Aroca	24	1996	A	M	LA+RA	LA+RA*	
Alami	28	1996	A		LA	LA	

**Three recurrences between 1983 and 1992*

Abbreviations

A: adult F: female M: male
 LA: left atrium LV: left ventricle RA: right atrium RV: right ventricle

Table 2: Series dealing with myxomas in the literature

Author	Reference	Year	Patients	Recurrence(s)
Gray	17	1985	14	2
McCarthy	1	1986	56	3 (1 second recurrence)
Nasser	14	1990	14	1
Tschirkov	6	1990	63	None
Loire	13	1991	85	6
Meyns	5	1993	32	None
Gotoh	8	1993	17	None
Duveau	12	1993	56	5 (4 second recurrence)
Yamamoto	7	1995	22	None
Bjessmo	29	1997	63	1
Lukacs	9	1997	50	None

Ohshima et al²² reported a familial cardiac myxoma with multiple and contralateral recurrence. The report described a familial recurrent cardiac myxoma involving a mother and her daughter. The mother had developed recurrent multiple myxomas at 27 years of age, four years after surgical excision of left atrial myxoma in both left and right atrium, and right ventricle. In an asymptomatic 13 year old daughter a recurrent left atrial myxoma was found three years after excision of a right atrial myxoma. Aroca et al²⁴ reported multiple recurrence of sporadic, non-familial cardiac myxoma. The patient underwent complete resection of myxoma three times within nine years.

Because of the possibility of recurrence, postoperative follow-up of all patients with cardiac myxoma is mandatory.²³ Besides transthoracic echocardiography, transoesophageal echocardiography may be used for both diagnosis^{21,25} and follow-up²¹ of cardiac myxomas. In the last few years, recurrent of myxomas is less frequently reported, and this may be due to improvement of surgical techniques, equipment and also experience.

References

1. McCarthy PM, Piehler JM, Schaff HV, Pluth JR, Orszulak TA, Vidaillet HJ, Carney JA. The significance of multiple, recurrent, and "complex" cardiac myxomas. *J Thorac Cardiovasc Surg* 1986;91:389-396
2. Carney JA. Differences between nonfamilial and familial cardiac myxoma. *Am J Surg Pathol* 1985;9:53-55
3. Pathi VL, Royse A, Doig W, Pollock JC. Left atrial myxoma in a preschool child. *Ann Thorac Surg* 1997;63:550-552
4. Pasaoglu I, Dogan R, Oram A, Ruacan S, Bozer Y. Familial atrial myxoma. *Eur J Cardiothorac Surg* 1991;5:388-390
5. Meyns B, Vancleemput J, Flameng W, Daenen W. Surgery for cardiac myxoma. A 20-year experience with long-term follow-up. *Eur J Cardiothorac Surg* 1993;7:437-440

6. Tshirkov A, Michev B, Topalov V, Michailov D, Jurukova Z, Petkov R. Incidences and surgical aspects of cardiac myxomas in Bulgaria. *Thorac Cardiovasc Surg* 1990;38 Suppl 2:196-200
7. Yamamoto K, Hayashi J, Maruyama Y, Ohzeki H, Tatebe S, Nakazawa S, Saitoh A, Namura O, Aguchi S. Surgical treatment of 22 primary cardiac myxomas. *Nippon Kyobu Geka Gakkai Zasshi* 1995;43:186-190
8. Gotoh Y, Kuribayashi R, Sakurada T, Sekine S, Aida H, Abe T, Atsumi H. Surgical treatment of cardiac myxomas. *Kyobu Geka* 1993;46:1115-1118
9. Lukacs L, Lengyel M, Szedo F, Haan A, Nagy L, Thomka I, Kassai I. Surgical treatment of cardiac myxomas: a 20-year follow-up. *Cardiovasc Surg* 1997;5:225-228
10. Takahashi T, Hada Y, Sakamoto T, Takenaka K, Amano K, Yamaguchi T, Ishimitsu T. Recurrent multiple cardiac myxomas: report of a case. *J Cardiogr* 1982;12:535-543
11. Martin LW, Wasserman AG, Goldstein H, Steinberg JS, Mills M, Katz RJ. Multiple cardiac myxomas with multiple recurrences: unusual presentation of a "benign" tumor. *Ann Thorac Surg* 1987;44:77-78
12. Duveau D, Baron O, Jegou B, Remadi JP, Michaud JL, Despins P, De Lajartre AY, Gaillard F. (Eng. Abstract) Multiple and recurrent cardiac myxomas. Is it a familial disease? *Chirurgie* 1993;119:357-361
13. Loire R, Termet H. (Article in French) Recurrence of intracardiac myxoma. A propos of 6 patients among 85 surgically treated. *Ann Cardiol Angeiol (Paris)* 1991;40:1-7
14. Nasser TK, Nasser WK, Slack JD, Noble RJ, Waller BF, Isch JH, Pinto RP. Cardiac myxoma: the Indiana Institute experience. *Indiana Med* 1990;83:644-647
15. Dang CR, Hurley EJ. Contralateral recurrent myxoma of the heart. *Ann Thorac Surg* 1976;21:59-62
16. Zeybek R, Basaran Y, Öztöp F. Recurrence of an atrial myxoma. *Int J Cardiol* 1991;33:435-437
17. Gray IR, Williams WG. Recurring cardiac myxoma. *Br Heart J* 1985;53:645-649
18. Fujiwara T, Kiso A, Nogami M, Nakai M, Yamane H, Kanazawa S, Katsumura T. Re-occurrence of left atrial myxoma in the right atrium. *Kyobu Geka* 1986;39:802-804
19. Pavlides GS, Levin RN, Hauser AM. Left ventricular recurrence of a resected left atrial myxoma. *Am Heart J* 1989;117:1390-1392
20. Soma Y, Ogawa S, Iwanaga S, Yozu R, Kudo M, Handa S, Kawada S, Sugiura H. Multiple primary left ventricular myxomas with multiple interventricular recurrences. *J Cardiovasc Surg (Torino)* 1992;33:765-767
21. Waller DA, Ettles DF, Saunders NR, Williams G. Recurrent cardiac myxoma: the surgical implications of two distinct groups of patients. *Thorac Cardiovasc Surg* 1989;37:226-230
22. Ohshima N, Yamada T, Nakahara H, Yokoyama M, Tanabe S, Irie Y, Fujisawa T. Familial cardiac myxoma with multiple and contralateral recurrence. *Kyobu Geka* 1990;43:1060-1066
23. Haught WH, Alexander JA, Conti CR. Familial recurring cardiac myxoma. *Clin Cardiol* 1991;14:692-695

24. Aroca A, Mesa JM, Dominguez F, Oliver JM, Ramirez U, Centeno JE. Multiple recurrence of a "sporadic" (non-familial) cardiac myxoma. Eur J Cardiothorac Surg 1996;10:919-921
25. Fagan LF Jr, Castello R, Barner H, Moran M, Labovitz AJ. Transesophageal echocardiographic diagnosis of recurrent right ventricular myxoma 2 years after excision of right atrial myxoma. Am Heart J 1990;120:1456-1458
26. Miyata Y, Takagi Y, Oohara Y, Ito T, Arika H, Oomiya T, Ishiara T, Konishi J. A case of biateral atrial myxoma. Kyobu Geka 1990;43:329-332
27. Jugdutt B I, Rosal R E, Sterns L P. An unusual case of recurrent atrial myxoma. Can Med Assoc J 1975;112:1099-1100
28. Alami A, Drissi K A, Chikaoui Y, Boumzebra D, Fares M, Rahali M, Belhaj S, Slaoni A, Maazouzi W. Double recurrence of myxoma of left atrium. Apropos of a case (Article in French). Ann Cardiol Angeiol 1996;45:585-587
29. Bjessmo S, Ivert T. Cardiac myxoma: 40 years' experience in 63 patients. Ann Thorac Surg 1997;63:697-700

Contact information

[Dr. Cevdet ERDÖL](mailto:ercedet@gul.net.tr)
KTÜ Faculty of Medicine
Dept. of Cardiology
61061 TRABZON - TÜRKIYE
Phone: +90 462 377 5379
Fax : +90 462 325 05 18
ercedet@gul.net.tr
