

IMAGES

in
PAEDIATRIC
CARDIOLOGY

Zain Z. Diffuse pulmonary arteriovenous malformation - a case report.
Images Paediatr Cardiol 2004;18:13-16

Department of Paediatric Cardiology, Faculty of Medicine, University of Malaya,
50603 Kuala Lumpur

Article

Patient

WZY is a 9 month old female infant. She was delivered by Caesarean section for unprovoked fetal distress and was admitted to the nursery for mild respiratory distress. She was treated for congenital pneumonia and discharged from the hospital completely well. Mild cyanosis of the lips, fingers and toes were noted as early as one month of age and cyanosis worsened when she cried or became fretful. Her colour improved when asleep and in the quiet resting state. She fed well with no symptoms of dyspnoea or sweatiness.

She was admitted at the age of three months for fever, poor feeding and increasing cyanosis. Examination revealed a centrally cyanosed child with an oxygen saturation of 65% in room air, rising to 75% in oxygen enriched air. There were no heart murmurs and the lung fields had vesicular breath sounds.

Haemoglobin level was 23.9 g/dl with haematocrit of 0.74. Arterial blood had a PaO₂ of 35 mmHg. Methaemoglobin and HB electrophoresis were normal. Chest X-ray showed prominent peripheral pulmonary vasculature and pulmonary artery (figure 1).

The electrocardiogram showed right axis deviation and right ventricular hypertrophy. Echocardiogram showed normal intracardiac structure and connections. The foramen ovale was patent with a left to right shunt. The pulmonary artery was enlarged. There was no significant valvular regurgitation. A contrast echocardiogram showed rapid return of contrast into the left atrium less than 5 seconds after it is seen in the right atrium (figure 2) and a diagnosis of diffuse-type pulmonary arteriovenous malformation (PAVM) was made.

Figure 1. Chest radiographic film showing prominent pulmonary vasculature and dilated pulmonary artery shadow

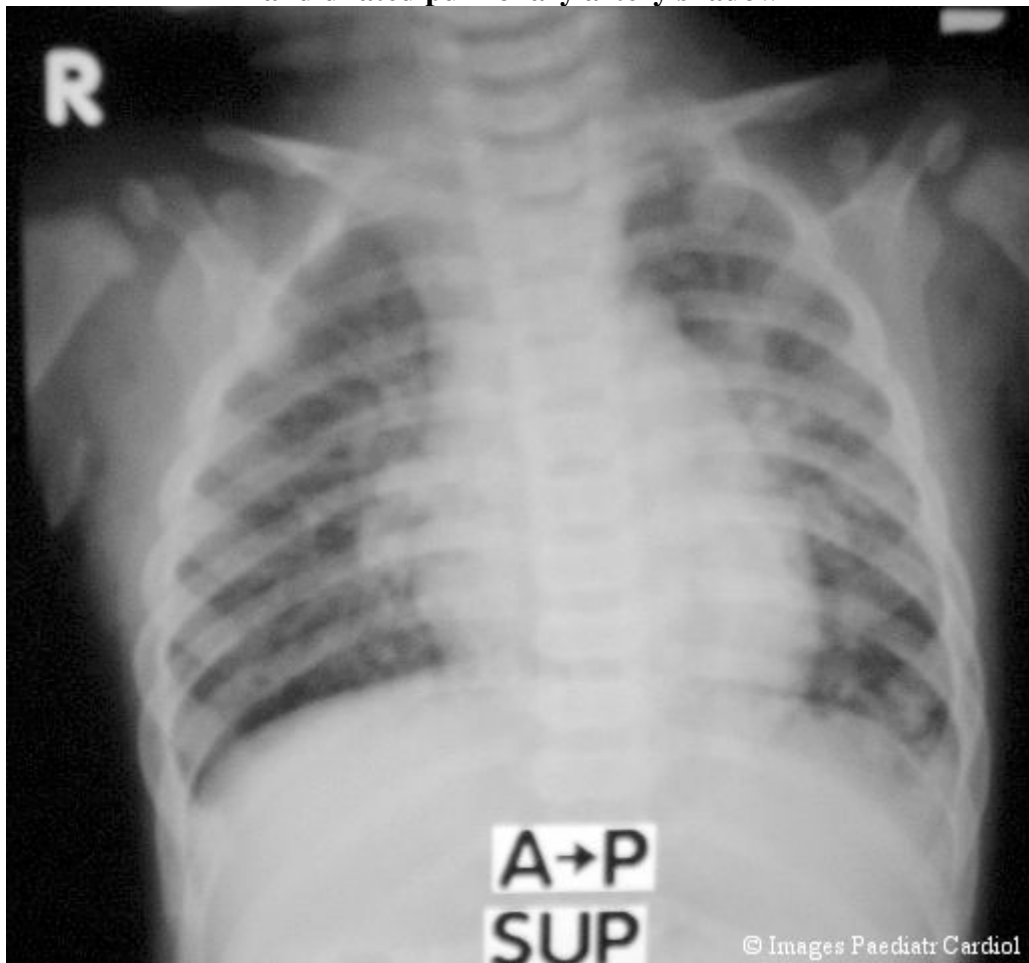
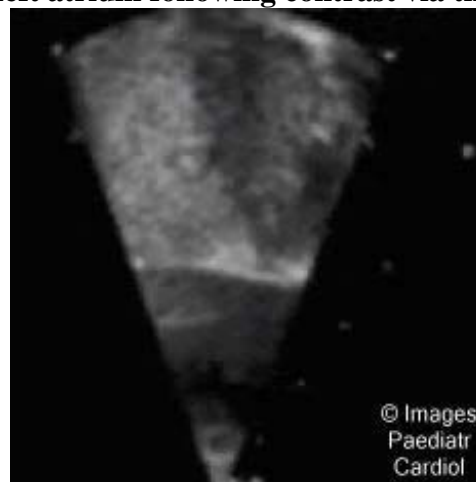


Figure 2. Subcostal view of echocardiographic contrast study showing the rapid filling of the left atrium following contrast via the right atrium



A thoracic CT scan was performed which showed prominent large vessels in the lower left lower lobe (figure 3) but not in any other organs. Cardiac catheterization showed normal pressures with desaturation in the left sided chambers. Pulmonary angiography showed multiple diffuse vascular lesions in the peripheries consistent with arteriovenous malformation (figure 4).

Figure 3. Thoracic CT scan showing multiple abnormal vascular formations highlighted by contrast

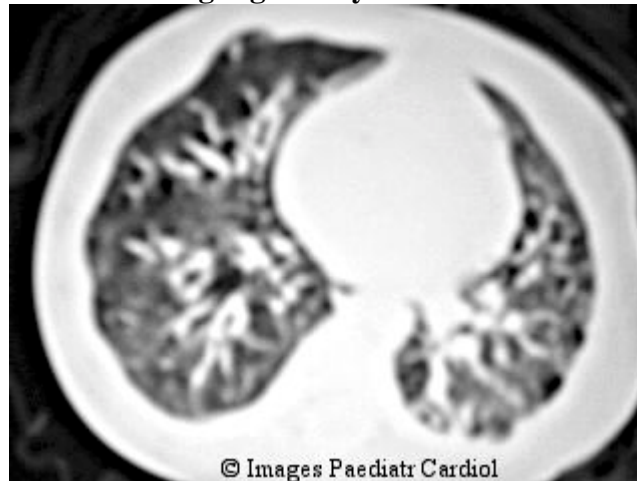
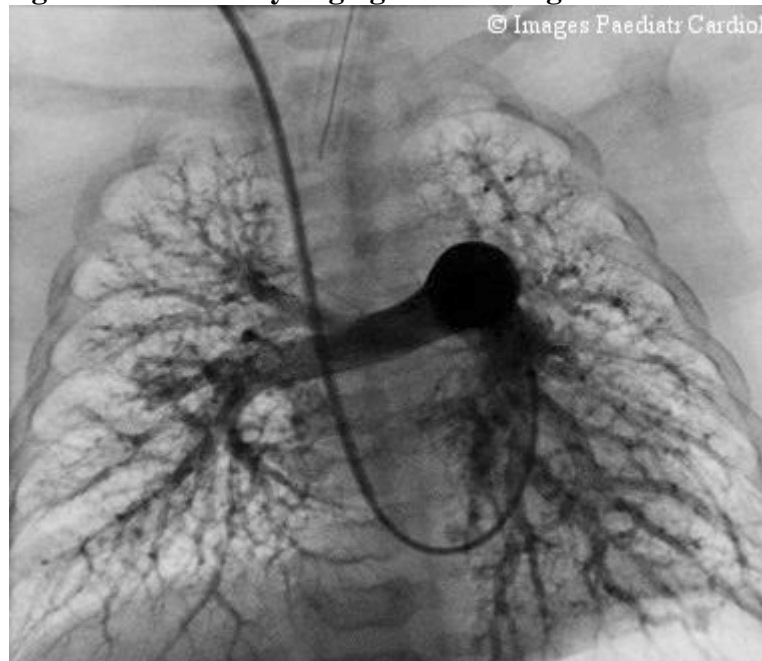

Figure 4. Pulmonary angiogram showing diffuse PAVMs



Discussion

Pulmonary arteriovenous malformations (PAVM) are direct communications between the smaller pulmonary arteries and veins. These are lesions in the vasculature that allow blood to bypass the capillary system, flowing from arteries directly into veins. These lesions are congenital in nature and are caused by failure of differentiation of the embryonic vascular plexus. These vessels expose the low resistance venous system to systemic pressures leading to abnormal vascular formations. Such lesions may be solitary and discrete or generally diffuse.¹

Patients may be asymptomatic in the milder forms, or have respiratory distress and haemoptysis in the severe types. The right to left shunt may be complicated by polycythaemia, cyanosis and cerebral abscesses.

The gold standard in diagnosis is pulmonary angiogram showing abnormal peripheral vascular formations that may be either localized or diffuse. Contrast echocardiography has been proven useful and accurate in screening for PAVM.² Due to the rapid transit of blood flow through the pulmonary veins into the capillaries, the left atrium is seen to be filled early with contrast (within 2-5 seconds) following contrast passage through the right atrium. Multi-slice computed tomography is also useful.³

Treatment of localized PAVMs includes surgical lobectomy or transcatheter embolization using coils. There is no definitive treatment for the diffuse type.

References

1. Higgins CB, Wexler L. Clinical and angiographic features of pulmonary arteriovenous fistulas in children. *Radiology* 1976;119:171-15.
2. Gossage JR. The role of echocardiography in screening for pulmonary arteriovenous malformations. *Chest* 2003;123:320-322
3. Coulier B. Detection of pulmonary arteriovenous malformations by multislice spiral CT angiography. *JBR-BTR* 2003;86:28

Contact information

[Dr. Zarin Zain](#)

Department of Paediatric Cardiology
Faculty of Medicine
University of Malaya
50603 Kuala Lumpur
zarin@ummc.edu.my

© Images in
Paediatric Cardiology
(1999-2004)

