

# IMAGES

## in PAEDIATRIC CARDIOLOGY

### **Falzon A<sup>1</sup>, Grech V<sup>1</sup>, DeGiovanni JV<sup>2</sup>. Delayed Amplatzer device closure of atrial septal defect for persistent cyanosis after surgical correction of severe pulmonary stenosis in early infancy. *Images Paediatr Cardiol* 2004;18:1-5**

<sup>1</sup> Paediatric Department, St. Luke's Hospital, Malta

<sup>2</sup> Cardiology Department, Birmingham Children's Hospital, Birmingham, UK

#### **Abstract**

We present two patients who had delayed transcatheter closure of secundum atrial septal defects for persistent cyanosis after surgical repair of severe pulmonary stenosis. The defects (two in one patient) were closed uneventfully and successfully with Amplatzer ASO devices, with significant improvement in oxygen saturation. The staged approach and the complementary role of surgery and intervention are discussed.

#### **MeSH**

Heart Septal Defects, Atrial

Child

Thoracic Surgery

Amplatzer ASO device

Heart Catheterization

Prostheses and Implants

Pulmonary Valve Stenosis

#### **Article**

##### **Introduction**

Severe pulmonary stenosis (PS) may present in early infancy with cyanosis and require urgent treatment with balloon dilation and/or surgical repair.<sup>1</sup> Cyanosis may persist, due to right to left shunting at atrial level, despite a good result until the right ventricular pressure drops and diastolic compliance improves; occasionally, the latter remains abnormal.<sup>1</sup>

An atrial communication is essential to maintain life in patients with critical or very severe PS; true atrial septal defects (ASD), as opposed to patent foramen ovale, not uncommonly co-exist with pulmonary stenosis. Large ASDs result in volume overload of the right heart due to left to right shunting, which can lead to an increase in pulmonary vascular resistance and atrial arrhythmias. Shunt reversal or bi-directional shunting can lead to paradoxical embolisation. Following pulmonary valvotomy, right ventricular overload may also result from pulmonary regurgitation and this may encourage right to left shunting through the atrial septum.

ASDs may close spontaneously in childhood.<sup>2</sup> Persistent defects with pulmonary to systemic flow ratios (Qp/Qs) of >1.5 are closed before school age or whenever a diagnosis is made, if this is later.<sup>3</sup> A variety of devices for transcatheter closure of ASDs have been developed and offer an alternative to surgical treatment.<sup>4</sup>

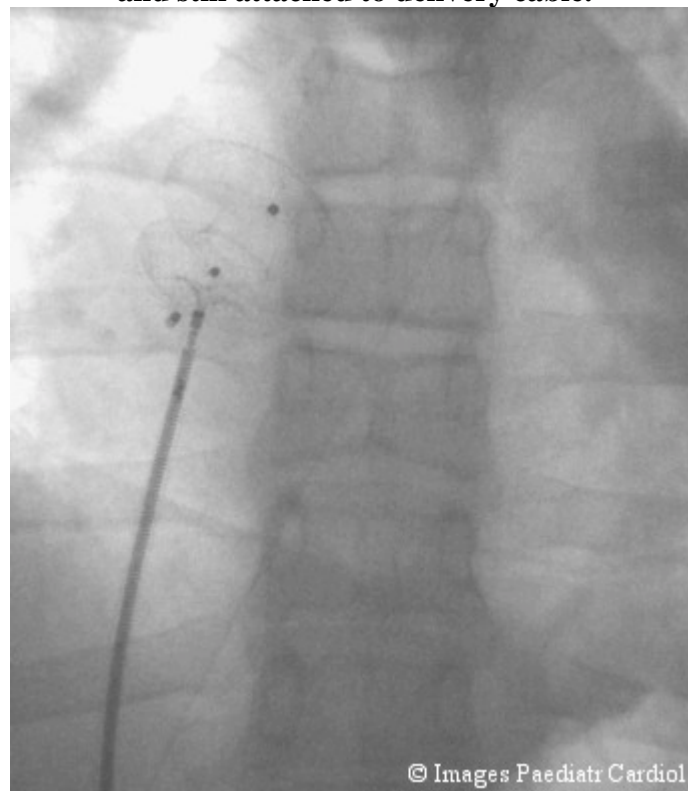
We present two patients who had severe pulmonary stenosis with attempted balloon dilation in early infancy. The procedures failed in both cases and surgery was successfully undertaken. Both children had persistent cyanosis due to residual atrial septal defects. In both children, the defects were successfully closed with Amplatzer devices (two devices in one child) with significant improvement in oxygen saturation.

## **Patients**

### **Case 1**

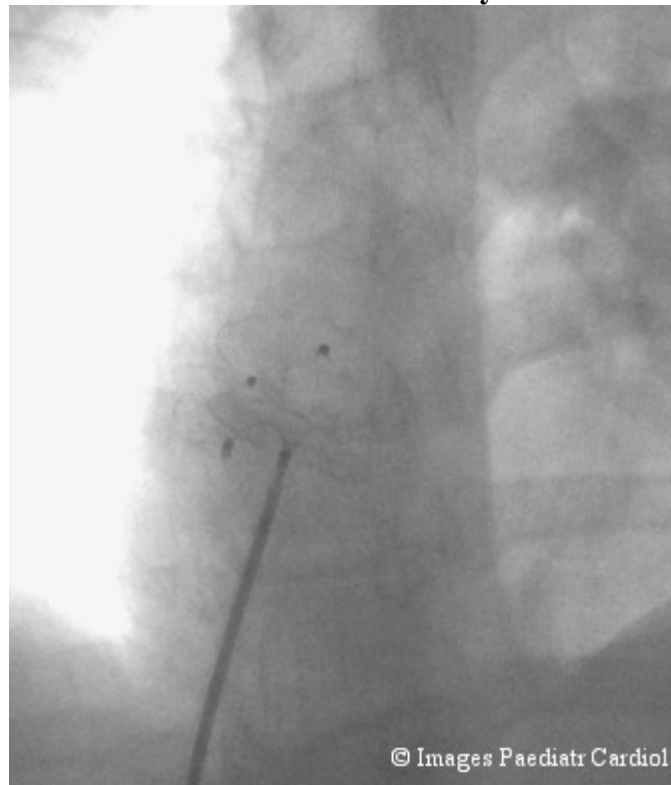
This child was born with severe pulmonary stenosis. An attempted valve balloon dilation in the neonatal period failed as the pulmonary valve could not be crossed. A transannular patch from right ventricle to pulmonary artery was performed at two months of age at a tertiary centre after urgent transfer. He also had a Ramstedt procedure for pyloric stenosis in infancy. He remained well but was persistently cyanosed with saturations in the mid 80's associated with clubbing. Clinical signs of significant pulmonary stenosis and incompetence were present. Echocardiography showed a 20mm atrial septal defect shunting bidirectionally and pulmonary valvar stenosis with a gradient of 40mmHg with moderate incompetence. At twelve years of age, transoesophageal echocardiography confirmed the presence of pulmonary stenosis and two atrial septal defects. The defects were successfully closed with 17 and 19 mm Amplatzer ASO devices after appropriate balloon sizing (figures 1 and 2).

**Figure 1: First Amplatzer ASO device deployed. Second device being deployed, and still attached to delivery cable.**



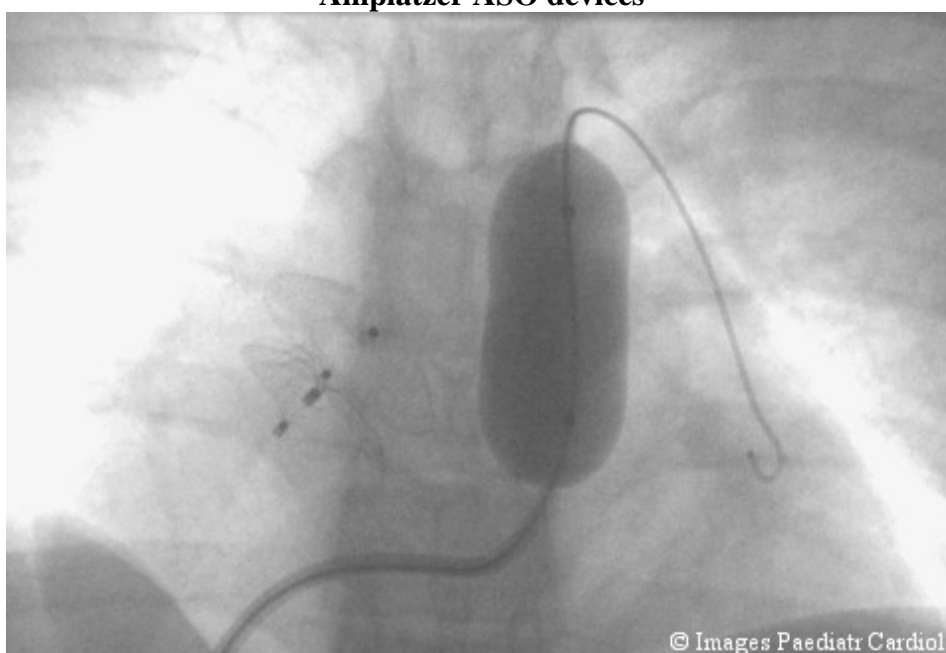
© Images Paediatr Cardiol

**Figure 2: First Amplatzer ASO device deployed. Second device being deployed, and still attached to delivery cable.**



Right ventricular pressure was 56mmHg and pulmonary artery pressure was 18mmHg. The pulmonary valve was dilated with a 23mm balloon with abolition of the waist (figure 3). The gradient dropped from 38 to 26 mmHg. Oxygen saturation three months after the procedure was 95%.

**Figure 3: Pulmonary valve being ballooned after successful deployment of both Amplatzer ASO devices**



### **Case 2**

This child also had severe pulmonary stenosis with failed catheter dilation. A transannular patch from right ventricle to pulmonary artery was performed along with pulmonary valvectomy at a tertiary centre after urgent transfer at six weeks of age. She remained well but was persistently cyanosed with saturation of 80% associated with clubbing and with clinical signs of moderate pulmonary incompetence. Echocardiography showed a 8mm atrial septal defect shunting bidirectionally and confirmed moderate pulmonary incompetence. At nine years of age, the ASD was successfully closed with a 9 mm Amplatzer device. Oxygen saturation three months after the procedure was 89%.

In both cases, the children and their parents have noted improvement in colour and exercise tolerance.

### **Discussion**

Balloon valvuloplasty is the treatment of choice for critical or severe pulmonary stenosis and also for pulmonary atresia with intact septum once the atretic valve is crossed by laser or radiofrequency perforation. Failed intervention usually reflects the pathology of the valve (dyplastic) or hypoplasia of the pulmonary valve ring/right ventricle. In these two cases, the fact that the surgeon needed to perform a transannular patch implies not only that the valve was stenosed, but also that the valve ring was small.

Although both balloon and surgical valvotomy/valvuloplasty can relieve the right ventricular obstruction, improvement in right ventricular function usually takes time. Systolic function often improves rapidly but diastolic compliance can remain abnormal for many weeks, months or even years. Because of this, it is sometimes necessary to maintain ductal patency with prostaglandin for some weeks even after successful valvotomy; if surgery is carried out, the duct should be left untouched for this reason. For the same reason, leaving an atrial communication patent helps to minimize a rise in systemic venous pressure but at the potential expense of cyanosis.

The indication for closing an ASD depends on the degree of cyanosis, the result of the valvotomy and also on the size of the right ventricle. If the latter is hypoplastic, closing an ASD may be contra-indicated. If the right ventricle is well developed but demonstrates impaired diastolic compliance, this will lead to cyanosis from right to left shunting at atrial level; the latter may be made worse when severe pulmonary regurgitation arises. Finally, there is also an indication to close an ASD if this is causing a large left to right shunt in the absence of cyanosis.

The timing of ASD closure is dependent on the severity of cyanosis or right ventricular volume overload but early closure is not essential. Improvement in pulmonary vascular resistance and right ventricular diastolic function may indeed reduce the level of cyanosis. If serial echocardiograms show no reduction in ASD size, a decision to close the defect is made and, depending on the size, shape and position, this can be done surgically or by a transcatheter technique; if feasible, the latter is preferable. Additional procedures, such as further valvotomy, may also determine the approach.

Technically, the method of ASD closure in patients who had a previous pulmonary valvotomy is identical to that for an isolated ASD. In cases where the right ventricular size or function are borderline, temporary test occlusion of the ASD with a compliant balloon may be necessary prior to device closure depending on the haemodynamic response i.e. cardiac output and right atrial pressure. If the right atrial pressure rises to unacceptable levels during temporary ASD occlusion, an alternative to the standard Amplatzer ASD device is to implant a fenestrated Amplatzer ASD device; this will reduce the atrial shunt but allow some flow to minimize the rise in right atrial pressure. Where feasible, the transcatheter approach is preferable to open heart surgery and the interventional approach is also possible when there are multiple ASDs, as shown in the first case of this report. Around two thirds of multiple ASDs can be closed with one device whereas the remaining third will require two or more devices. Multiple device implantation, when required, can be carried out during one sitting. Indeed, a recent study involving 3535 patients who had Amplatzer ASD device closure showed that 1.3% needed two devices to be implanted to close two separate defects.<sup>5</sup>

If cyanosis persists after closure of atrial communication/s, it is important to exclude other atrial defects, pulmonary arterio-venous malformations and anomalous drainage of a systemic vein to the left side of the heart.

This report highlights the staged approach to critical/severe pulmonary stenosis, the combination of surgical and interventional methods as well as the importance of the timing and of case selection for late closure of atrial communications.

## References

1. Latson LA. Critical pulmonary stenosis. *J Interv Cardiol* 2001;14:345-350
2. Radzig D, Davignon N, Van Doesburg, Fournier A, Marchand T, Ducharme G. Predictive factors for spontaneous closure of ASDs diagnosed in the first 3 months of life. *J Am Coll Cardiol* 1993;22:851-853
3. Kirklin JW, Barratt-Bouyes G: *Cardiac Surgery*. Second Edition; Churchill Livingstone, pp. 609-644, 1993
4. Ebeid MR. Percutaneous catheter closure of secundum atrial septal defects: a review. *J Invasive Cardiol* 2002;14:25-31
5. Young D. Later results of closure of secundum atrial septal defects in children. *AM J Card* 1973;31:16-22

---

### Contact information



[Dr. Victor Grech](#)

Editor-in-Chief

Images Paediatr Cardiol

[victor.e.grech@gov.mt](mailto:victor.e.grech@gov.mt)

---

© Images in  
Paediatric Cardiology  
(1999-2004)

